

Fibrin-Assisted Soft Tissue Promotion

A Paradigm Shift in Periodontal Plastic Procedures


Alexandre Amir Aalam, DDS
Alina Krivitsky Aalam, DDS
Joseph Choukroun, MD

Abstract

The purpose of periodontal plastic surgery is to correct the lost attachment apparatus and the soft tissue deformities associated with periodontal disease. Multiple surgical techniques associated with the harvest of autogenous soft tissue grafts (free gingival or subepithelial connective tissue grafts) or the use of donor tissues are described in the literature and are associated with increased morbidity, cost, and safety issues. Advanced platelet-rich fibrin (APRF) represents the third generation of blood-derived growth factors widely used in medicine and periodontics. Fibrin-assisted soft tissue promotion is a simple surgical technique associated with the use of APRF as a source of autogenous growth factors that allow the recipient soft tissue to promote the fabrication of new keratinized and attached tissue without a donor site.

Key Words: recession, platelet-rich fibrin, periodontal plastic surgery, tissue graft alternative, blood-derived growth factors

“ In cases that involve multiple adjacent teeth with recession, there is a considerably greater amount of avascular exposed root surface, making repair more invasive and less predictable due to reduced blood supply to the surgical site. ”



Introduction

Gingival recession is associated with attachment apparatus loss. In cases that involve multiple adjacent teeth with recession, there is a considerably greater amount of avascular exposed root surface, making repair more invasive and less predictable due to reduced blood supply to the surgical site. Multiple periodontal plastic surgery procedures have been proposed to correct these mucogingival deformities and, thus, rebuild the lost attachment apparatus and increase the zone of attached and keratinized tissue that is required for long-term maintenance of a healthy dentition.^{1,2} These traditional techniques require the addition of soft tissue harvested either from the patient (from the palate or a tuberosity) or from another donor origin (allograft or xenograft).³ Such techniques are associated with increased morbidity (harvesting site), risk of infection (disease transmission), and cost (for biomaterials).

Blood-derived growth factors, initially represented by platelet-rich plasma, have been used successfully in dentistry.⁴ Advanced platelet-rich fibrin (APRF),⁵⁻⁸ the third generation of blood derivatives—in the form of fibrin membranes filled with leukocytes, growth factors, and stem cells—is used in combination with bone graft materials for periodontal regeneration, sinus grafting, and ridge augmentation. APRF has been used in periodontal plastic surgery for the purpose of root coverage.⁹⁻¹⁵ This article presents fibrin-assisted soft tissue promotion (FASTP) as an alternative to a conventional root coverage procedure, using APRF membranes as a source of growth factors to promote the formation of new keratinized and attached tissue at the recipient site.

Case Presentation

A 42-year-old female presented with a chief complaint of receding gums. She wanted an alternative to traditional gum grafting using autogenous subepithelial connective tissue graft. Her medical history was unremarkable and was classified as ASA I.¹⁶ Her dental history revealed a three-year orthodontic treatment coupled with maxillary orthognathic surgery to correct malocclusion and improve jaw alignment. Her periodontal evaluation, limited to the maxillary anterior sextant, revealed the following:

- periodontal pocket depths ranging from 1 to 3 mm
- gingival recession ranging from 1 to 4 mm
- mild horizontal bone loss.

She was diagnosed with Miller Class II and III trauma-induced gingival recession, the latter with interproximal attachment loss (**Fig 1**).¹⁷ The prognosis was good for the increase in volume of the keratinized and attached tissue and was an expected 90% for the root coverage (due to mild bone loss).

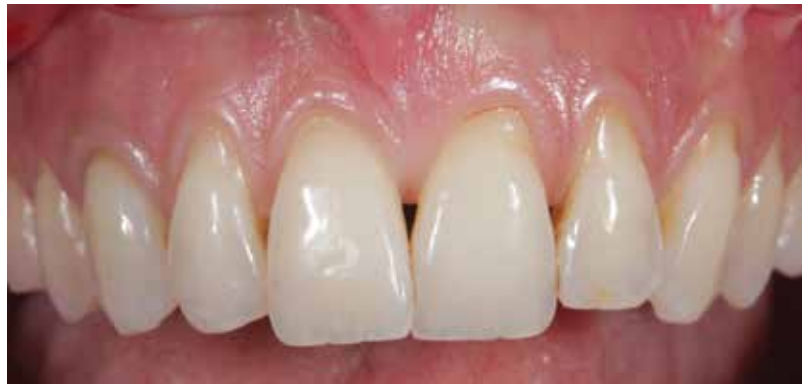

Figure 1: Preoperative image showing gingival recession on the maxillary anterior sextant.

// Blood-derived growth factors, initially represented by platelet-rich plasma, have been used successfully in dentistry. //

Treatment

FASTP is a simplification of the vestibular incision subperiosteal access technique, in which a vertical incision is made into the mucosal area, allowing a horizontal full thickness flap dissection and insertion of the graft; and an improvement of the tunnel technique,¹⁸⁻²⁰ in which a full thickness flap is elevated through the sulcus of the teeth without lifting the papillae. The graft is inserted through the sulcus of the teeth.

APRF Membrane Preparation

Each 10 ml of blood drawn will produce one APRF membrane. Three to four membranes are recommended for each pair of treated teeth. The APRF tubes are spun in a centrifuge (Process Ltd.; Nice, France) at 1300 rpm for eight minutes.⁸ The fibrin clots formed are filled with growth factors, stem cells, and leukocytes. The clots are compressed in a special container (PRF box, Process Ltd.) and formed into membranes that can be used for the clinical application (Figs 2-4).

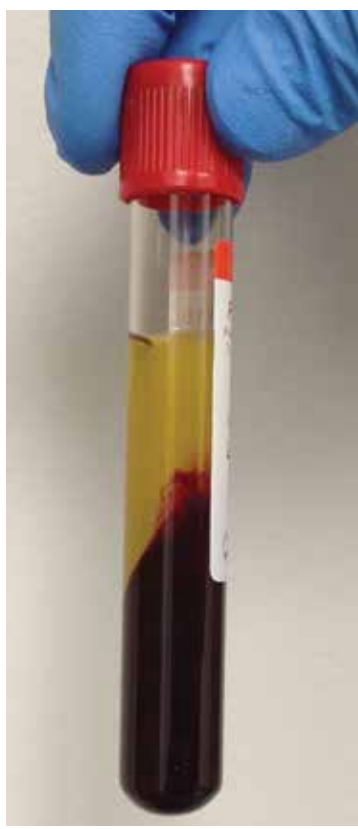

Figure 2: A 10-ml APRF tube with the fibrin clot obtained after centrifugation. Note the separation, with the red corpuscles at the bottom of the tube.

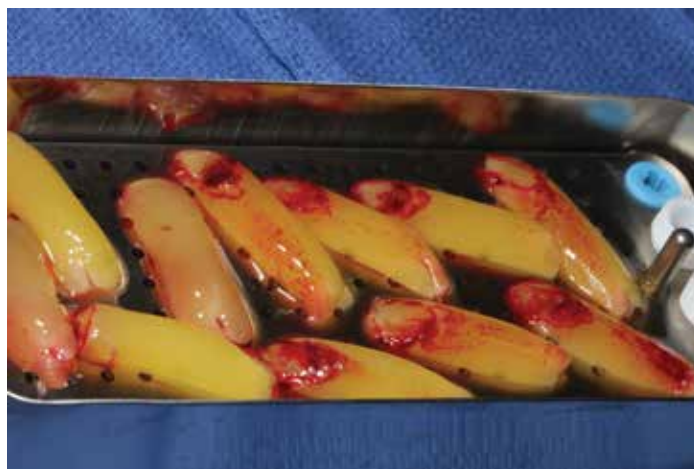

Figure 3: The APRF clots are placed into the PRF box, ready to be compressed. Note that the red corpuscles are discarded.

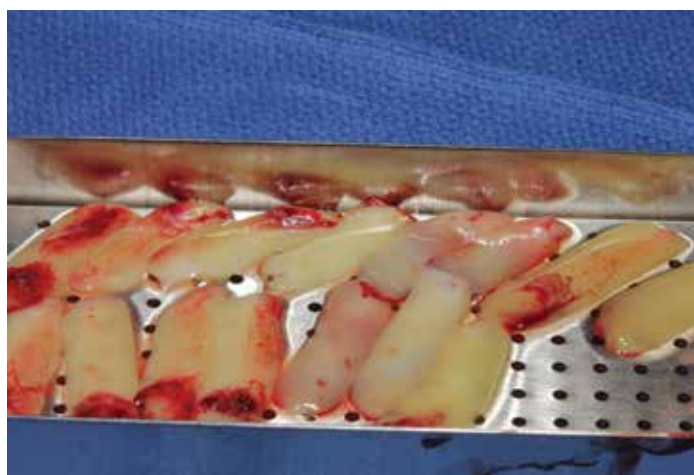

Figure 4: The APRF membranes are fabricated after pressing the cover of the PRF box until a uniform membrane is created.

Incision

The vertical mucosal incision (Fig 5) will allow a horizontal (mesiodistal) and vertical (apicocoronal) full thickness flap, resulting in total flap relaxation and passive coronal displacement of the mucogingival-papillary complex (Figs 6 & 7).²¹

Root Preparation and Decontamination

These procedures were performed as follows:

- Thorough root preparation to create a flat or negative root surface allows for more volume of APRF to be inserted and decreases flap tension. This leads to minimal APRF membrane resorption, or biotensegrity (the impact on the cytoskeleton of a cell and thus the fundamental phenotype changes resulting from pressure exerted from the extra cellular matrix).
- Root decontamination using ethylenediaminetetraacetic acid (EDTA) 17% (double application for two-and-a-half minutes) removes the smear layer created by root planing/preparation. It allows the collagen in the dentinal fibers to be exposed and improves the quality of the anticipated attachment (Fig 8).

// FASTP is a simplification of the vestibular incision subperiosteal access technique... //

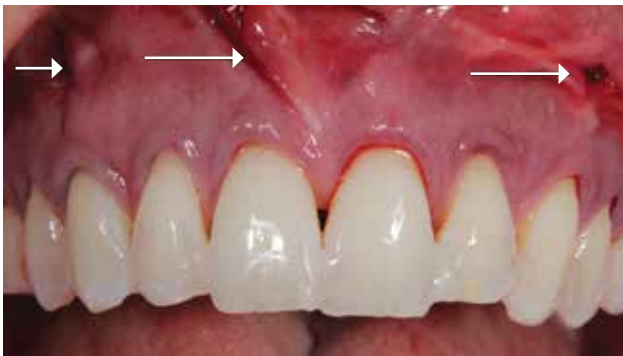

Figure 5: Three vertical incisions in the mucosa allow for a horizontal instrumentation of the flap (white arrows). Flowable composite is placed in between the teeth to retain sutures.

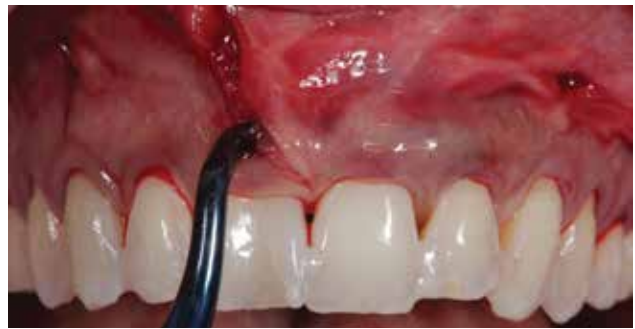

Figure 6: Complete flap relaxation is obtained by raising a full thickness flap. The papillae are elevated but not separated from the flap.



Figure 7: Offset curettes used to achieve the flap dissection.

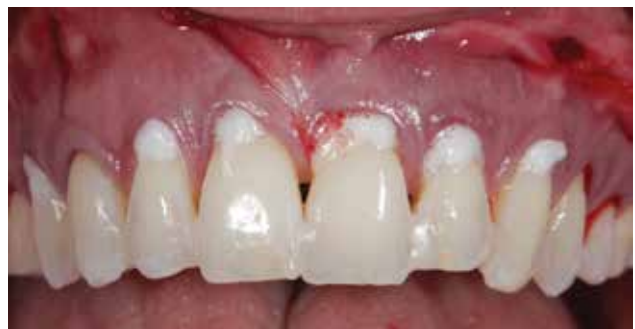

Figure 8: The roots are planed and detoxified twice with EDTA 17% for two-and-a-half minutes and rinsed copiously.

APRF Volume

The authors recommend a minimum of three to four membranes per pair of teeth to see clinical significance. A “backpacking” concept from distal to mesial provides a homogenous density of APRF membrane volume (Fig 9). As a result, the flap is physiologically displaced coronally without any tension. This tension-free concept is the core of the clinical application of biotensegrity (Fig 10).²² Clinically, excessive flap tension will induce a premature resorption of the APRF membranes and thus a lack of growth factor released, translating to a reduction of keratinized tissue formation.

Suturing

Two layers of suturing are proposed:

- Apical periosteal mattress sutures are the core of the suturing technique and have two purposes: to avoid marginal suture tension on the APRF membranes, and to stabilize and maintain the membranes on the root surfaces and avoid any displacement of the membranes into the mucosal area. Polypropylene 5.0 sutures are recommended (Prolene, Henry Schein; Chatsworth, CA) (Fig 11).
- Interproximal sling sutures are used to position the flap coronally. Polypropylene 6.0 sutures are recommended (Fig 12).

A flowable composite (Elegance, Henry Schein) was used between the teeth without any preparation (no etching or primer). The shrinkage after light-curing physically locks the composite material between the teeth and provides support for the sutures. Approximately two-and-a-half weeks later, the sutures were removed and the composites separated from the incisal edges of the teeth with a curette (Fig 13).

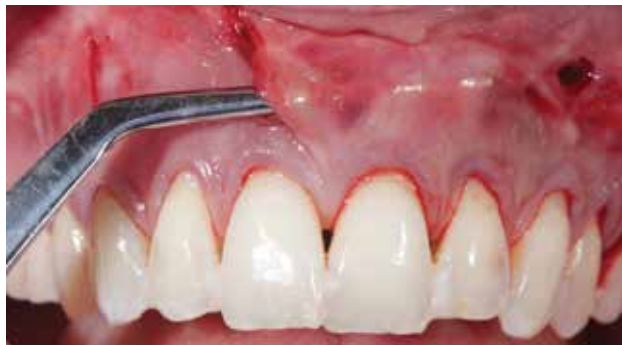

Figure 9: The APRF membranes are inserted from distal to mesial. Three to four membranes are used per pair of teeth.

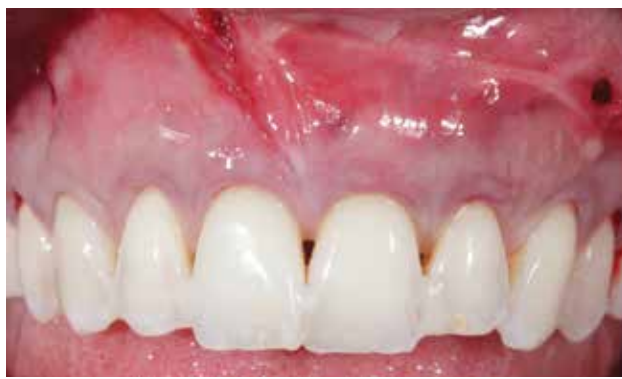

Figure 10: The complete flap relaxation combined with adequate volume of APRF membranes displaces the flap coronally without tension.

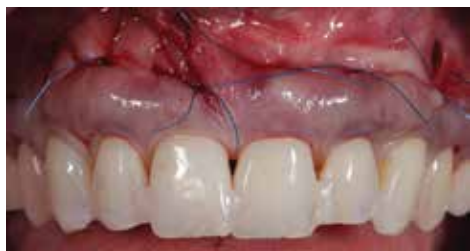

Figure 11: Deep apical mattress sutures keep the APRF membranes on the roots and protect the flap against vertical muscles of mastication pull.

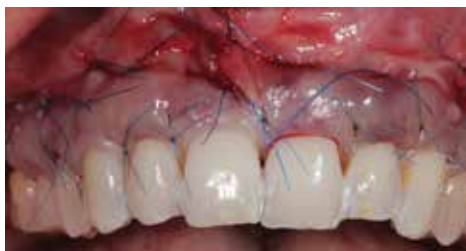

Figure 12: Interproximal sling sutures coronally advance the flap on the roots.

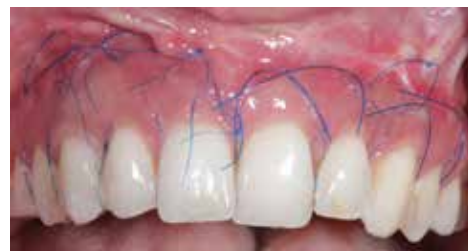

Figure 13: Two weeks postoperative; note the uneventful healing.

Discussion and Summary

Root coverage predictability and increase of the zone of keratinized tissue depend upon multiple factors that are equally important (Fig 14):

- a comprehensive understanding of the APRF mechanism of action and biological principles
- a precise execution of the surgical technique that relies on:
 - flap relaxation
 - easy access to membrane insertion and positioning on roots (volume)
 - physiological coronal displacement of the flap (biotensegrity)
 - passive closure without tension.

FASTP is a paradigm shift in the field of periodontal plastic surgery. Soft tissue promotion is an attractive concept that allows the practitioner to treat more advanced and extensive cases without the need to harvest tissue from a donor site. A decrease in procedure-related morbidity (postoperative pain and discomfort), as well as an increase in case acceptance, was observed. This case report has introduced a novel approach for root coverage treatment with a positive and stable outcome over two years. However, double-blinded prospective studies comparing fibrin-assisted soft tissue promotion to the traditional existing techniques are needed.

References

1. Zucchelli G, De Sanctis M. Treatment of multiple recession-type defects in patients with esthetic demands. *J Periodontol.* 2000 Sep;71(9):1506-14.
2. Zabalegui I, Sicilia A, Cambra J, Gil J, Sanz M. Treatment of multiple adjacent gingival recessions with the tunnel sub-epithelial connective tissue graft: a clinical report. *Int J Periodontics Restorative Dent.* 1999 Apr;19(2):199-206.
3. Aichelmann-Reidy ME, Yukna RA, Evans GH, Nasr HF, Mayer ET. Clinical evaluation of acellular allograft dermis for the treatment of human gingival recession. *J Periodontol.* 2001 Aug;72(8):998-1005.
4. Marx RE. Platelet-rich plasma: evidence to support its use. *J Oral Maxillofac Surg.* 2004 Apr;62(4):489-96.
5. Dohan DM, Choukroun J, Diss A, Dohan SL, Dohan AJ, Mouhyi J, Gogly B. Platelet-rich fibrin (PRF): a second-generation platelet concentrate. Part II: platelet-related biologic features. *Oral Surg Oral Med Oral Pathol Oral Radiol Endod.* 2006 Mar;101(3):e45-50.

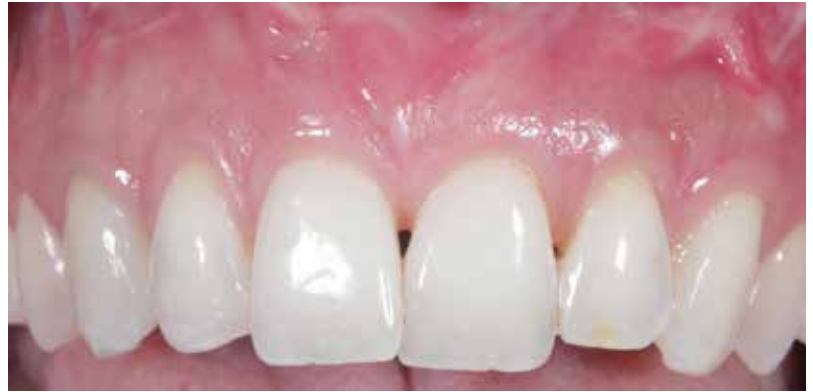

Figure 14: Two years postoperative; note the complete root coverage and the increase of keratinized and attached tissues.

6. Dohan DM, Choukroun J, Diss A, Dohan SL, Dohan AJ, Mouhyi J, Gogly B. Platelet-rich fibrin (PRF): a second-generation platelet concentrate. Part III: leukocyte activation: a new feature for platelet concentrates? *Oral Surg Oral Med Oral Pathol Oral Radiol Endod.* 2006 Mar;101(3):e51-5.
7. Choukroun J, Diss A, Simonpieri A, Girard MO, Schoeffler C, Dohan AJ, Mouhyi J, Dohan DM. Platelet-rich fibrin (PRF): a second-generation platelet concentrate. Part IV: clinical effects on tissue healing. *Oral Surg Oral Med Oral Pathol Oral Radiol Endod.* 2006 Mar;101(3):e56-60.
8. Choukroun J, Arun S. [Advanced platelet-rich fibrin. A new gold standard in blood-derived growth factors]. *Stomatologie.* 2014;59(13):21-8. French.
9. Aroca S, Keglévich T, Barbieri B, Gera I, Etienne D. Clinical evaluation of a modified coronally advanced flap alone or in combination with a platelet-rich fibrin membrane for the treatment of adjacent multiple gingival recessions: a 6-month study. *J Periodontol.* 2009 Feb;80(2):244-52.
10. Jankovic S, Aleksic Z, Milinkovic I, Dimitrijevic B. The coronally advanced flap in combination with platelet-rich fibrin (PRF) and enamel matrix derivative in the treatment of gingival recession: a comparative study. *Eur J Esthet Dent.* 2010 Autumn;5(3):260-73.
11. Jankovic S, Aleksic Z, Klokkevold P, Lekovic V, Dimitrijevic B, Kenney EB, Camargo P. Use of platelet-rich fibrin membrane following treatment of gingival recession: a randomized clinical trial. *Int J Periodontics Restorative Dent.* 2012 Apr;32(2):e41-50.
12. Zhang Y, Tangl S, Huber CD, Lin Y, Qiu L, Rausch-Fan X. Effects of Choukroun's platelet-rich fibrin on bone regeneration in combination with deproteinized bovine bone mineral in maxillary sinus augmentation: a histological and histomorphometric study. *J Cranio-maxillofac Surg.* 2012 Jun;40(4):321-8.
13. Pradeep AR, Sharma A. Autologous platelet-rich fibrin in the treatment of mandibular degree II furcation defects: a randomized clinical trial. *J Periodontol.* 2011 Oct;82(10):1396-403.

14. Mazor Z, Horowitz RA, Del Corso M, Prasad HS, Rohrer MD, Dohan Ehrenfest DM. Sinus floor augmentation with simultaneous implant placement using Choukroun's platelet-rich fibrin as the sole grafting material: a radiologic and histologic study at 6 months. *J Periodontol*. 2009 Dec;80(12):2056-64.
15. Sharma AR, Pradeep AR. Treatment of 3-wall intrabony defects in chronic periodontitis subjects with autologous platelet-rich fibrin: a randomized controlled trial. *J Periodontol*. 2011 Dec;82(12):1705-12.
16. American Society of Anesthesiologists (ASA). ASA Physical Status Classification System. Available from: <https://www.asahq.org/resources/clinical-information/asa-physical-status-classification-system>
17. Miller PD Jr. A classification of marginal tissue recession. *Int J Periodontics Restorative Dent*. 1985;5(2):8-13.
18. Allen AL. Use of the supraperiosteal envelope in soft tissue grafting for root coverage. I. Rationale and technique. *Int J Periodontics Restorative Dent*. 1994 Jun;14(3):216-27.
19. Azzi R, Etienne D. [Root coverage and papilla reconstruction by connective tissue graft inserted under a vestibular coronally advanced tunnelized flap]. *J Parodont Implant Orale*. 1998;17:71-7. French.
20. Zadeh HH. Minimally invasive treatment of maxillary anterior gingival recession defects by vestibular incision subperiosteal tunnel access and platelet-derived growth factor BB. *Int J Periodontics Restorative Dent*. 2011 Nov-Dec;31(6):653-60.
21. Pini Prato G, Pagliaro U, Baldi C, Nieri M, Saletta D, Cairo F, Cortellini P. Coronally advanced flap procedure for root coverage. Flap with tension versus flap without tension: a randomized controlled clinical study. *J Periodontol*. 2000 Feb;71(2):188-201.
22. Ingber DE. Tensegrity-based mechanosensing from macro to micro. *Prog Biophys Mol Biol*. 2008 Jun-Jul;97(2):163-79. **jCD**

// Each 10 ml of blood drawn will produce one APRF membrane. Three to four membranes are recommended for each pair of treated teeth. **//**



Dr. Alexandre Aalam is a clinical assistant professor, Department of Advanced Periodontics, Herman Ostrow School of Dentistry of USC. He maintains a private practice in Los Angeles, California.



Dr. Alina Krivitsky Aalam is a clinical assistant professor, Department of Advanced Periodontics, Herman Ostrow School of Dentistry of USC. She maintains a private practice in Los Angeles, California.



Dr. Choukroun maintains a private practice in Nice, France.

Disclosure: Dr. Choukroun developed the fibrin-assisted soft tissue promotion technique discussed in this article. He did not receive any financial remuneration for co-authoring the article.